

# CERVIX SAMPLING CARD



VCS Pathology

## A GUIDE TO TAKING A HIGH-QUALITY CERVICAL SAMPLE

If you would like to watch a video demonstrating the correct technique for taking a high-quality Cervical Screening Test (CST) visit [www.vcs.org.au/pathology/for-practitioners/general-resources/](http://www.vcs.org.au/pathology/for-practitioners/general-resources/)

For more information about CST technique, the new National Cervical Screening Program, and testing for HPV, contact VCS Pathology on 03 9250 0300 and ask to speak to a Liaison Physician or email [LiaisonTeam@acpcc.org.au](mailto:LiaisonTeam@acpcc.org.au)

## CERVICAL SCREENING: RECOMMENDED TECHNIQUES AND INSTRUMENTS FOR TAKING A CERVICAL SAMPLE

### FOR PRE-MENOPAUSAL WOMEN

**Cervical sampler broom:** rotate 3-5 times

or

**Cervex-Brush® Combi:** insert central part of the brush into os and rotate clockwise twice

or

**Spatula:** rotate once or twice, taking care to keep contact with the ecto-cervix  
**plus:**

**Endocervical brush:** insert ensuring that you can see the lower row of the bristles and make a quarter rotation

### FOR PERI AND POST-MENOPAUSAL WOMEN

**Cervical sampler broom:** rotate 3-5 times  
**plus:**

**Endocervical brush:** insert ensuring that you can see the lower row of the bristles and make a quarter rotation

or

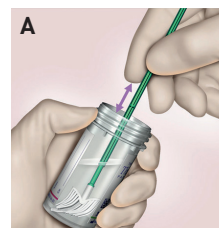
**Cervix-Brush® Combi:** insert central part of the brush into os and rotate clockwise twice

or

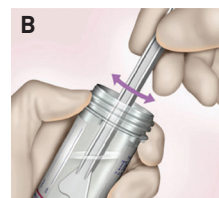
**Spatula:** rotate once or twice, taking care to keep contact with the ecto-cervix  
**plus:**

**Endocervical brush:** insert ensuring that you can see the lower row of the bristles and make a quarter rotation.

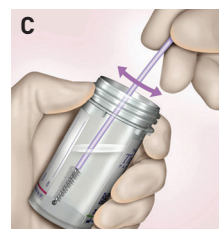
### FOR THINPREP



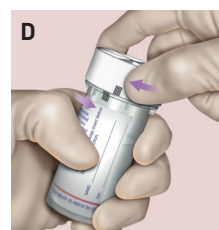
**A. Cervical sampler Broom / Cervex-Brush® Combi:** rinse the broom/brush as quickly as possible into the vial by pushing the broom into the bottom of the vial 10 times, forcing the bristles apart. As a final step, swirl the broom vigorously to further release material. Discard the collection device.



**B. Spatula (Plastic):** Rinse the spatula as quickly as possible into the vial by swirling the spatula vigorously in the vial 10 times. Discard the spatula.



**C. Endocervical Brush:** Rinse the brush as quickly as possible in the solution by rotating the device in the solution 10 times while pushing against the vial wall. Swirl the brush vigorously to release material. Discard the brush.



**D. Tighten** the cap so that the black line on the cap passes the black line on the vial.

Images supplied by Hologic (Australia) Pty Ltd

### RECORDING PATIENT DETAILS

**Record** the patient's surname, first name and date of birth on the vial.

OR

**Apply** sticker with details.

**Record** the patient's information and medical history on the request form.

### VCS IS ABLE TO PROCESS THINPREP AND SUREPATH


#### ThinPrep

- Do not leave any part of the sampling device in the fluid.

#### SurePath

- Instruments should be broken off and left in the fluid

### Sampling instruments



### SPECIAL NOTES

**Eversion:** take care to sample the squamo-columnar junction. This is the junction where the columnar epithelium of the endocervical canal meets the squamous epithelium of the vagina. It is the area where changes occur.

**Pregnancy:** do not use the endocervical brush or Cervex-Brush® Combi.

# CERVIX SAMPLING CARD



VCS Pathology

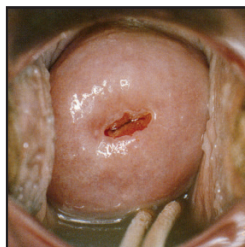
This resource is a guide for practitioners to assist them in identifying visual cervical appearances.

The images shown here are some examples of cervixes you may see when taking a cervical sample.

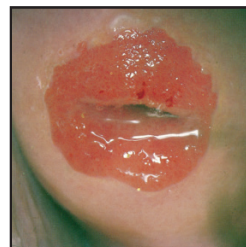Visual cervical abnormality may need further investigation even if screening tests are negative.

If you are uncertain about the appearance of the cervix, we recommend you seek a second opinion.

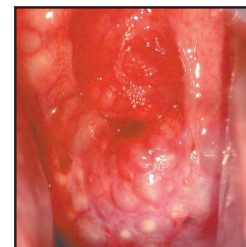**Further investigation not required in asymptomatic patients**



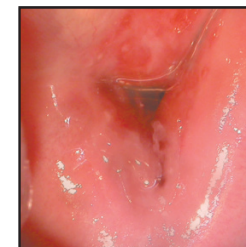Nulliparous<sup>1</sup>



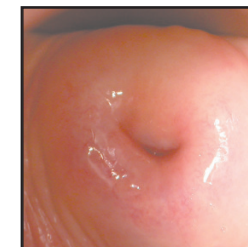
Eversion / ectropion



Nabothian follicles

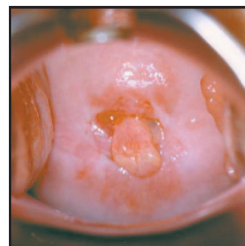


Multiparous

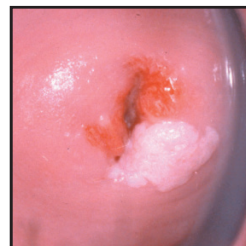

Atrophy

**Consider further investigation**

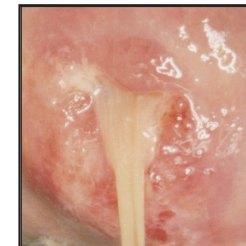


Polyp

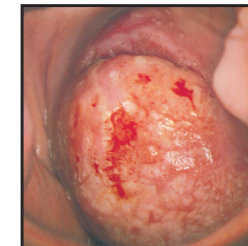

Cervical wart

**Should be investigated**

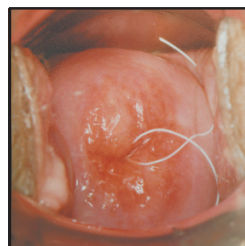


Mucopurulent discharge<sup>3</sup>

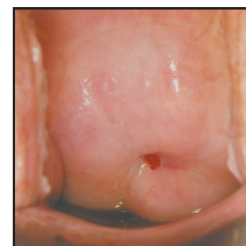


Cancer<sup>2</sup>

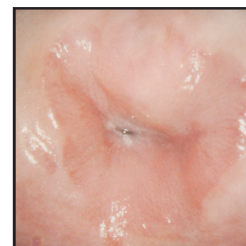
**Post-intervention - further investigation not required in asymptomatic patients**



Intra Uterine Device (IUD)



Stenosis



Post treatment<sup>2</sup>

Reproduced with permission from:

- 1 Wolfendale, Margaret, 1995. Taking Cervical Smears. British Society for Clinical Cytology: page 12.
- 2 Burghardt, Erich, 1984. Colposcopy Cervical Pathology Textbook and Atlas. Georg Thiem Verlag, Germany: pages 162 & 174.
- 3 Cartier, René, 1984. Practical Colposcopy. Laboratoire Cartier. Switzerland: page 168.